



## Simultaneous Cochlear Implantation with Translabyrinthine Removal of Vestibular Schwannoma

Katsumi Doi\*, Ko SHiraishi, Takeshi Fujita, Takamitsu Kobayashi, Mitsuo Sato, Kazuya Saito, Toru Seo, Kumi Kohama and Daisuke Nagatomi

Department of Otolaryngology, Kindai University School of Medicine, Japan

### Abstract

Decision making in patients with a vestibular schwannoma (VS) in the only hearing ear is challenging. Restoration of hearing when they become deaf will depend on the status of the remaining cochlear and the integrity and function of the cochlear nerve. In terms of hearing restoration, cochlear implantation (CI) is the most effective option if the cochlear nerve could be preserved intact and the cochlea could be remained responsive to electrical stimulation. Auditory Brainstem Implantation (ABI) would be another option for the patients in which the cochlear nerve could not be spared during VS removal, while the hearing results with ABI are still far poor than those with CI. If CI is being considered, it should be performed near the time of the surgery for VS removal, because cochlear fibrosis and/or ossification might occur in a short time after the surgery. When the translabyrinthine surgery (TLS) for VS removal is selected, CI surgery should be completed as close as possible to the procedure.

Simultaneous CI with TLS removal of VS was considered for the patient who suffered from a severe sensorineural hearing loss on the same side with VS and a profound deafness on the opposite side due to the past idiopathic sudden deafness. The first CI was preceded on the opposite side, and the second CI was performed on the tumor side one year after. Simultaneous CI with TLS VS removal is a good option that should be considered when discussing and planning the most appropriate strategy.

### Introduction

Hearing preservation is often difficult to achieve despite treatment of VS removal with surgery even with hearing preservation techniques are employed [1]. Therefore, the resection of VS for the patients with only hearing or better hearing on the tumor side ear is still controversial. In profoundly deaf patients or patients where treatment is likely to cause severe hearing deterioration, cochlear implantation (CI) or auditory brainstem implantation (ABI) provide the best two options for hearing outcomes [1-3]. CI surgery may be of benefit if the cochlear nerve could be preserved after tumor removal, while ABI should be considered if the cochlear nerve preservation would not be predicted. Some authors reported that VS removal with simultaneous CI is another option for those cases and the hearing results with CI were shown to be excellent mostly [1-5].

We present a case in which L-CI was firstly performed on the opposite side, and then R-VS removal surgery via translabyrinthine approach with simultaneous R-CI on the tumor side was conducted one year later.

### Case Presentation

A 50-year-old woman presented in our hospital suffering from sudden onset hearing loss on the left ear in 2005. A pure tone audiogram showed 91.7 dB SNHL on the left side and 36.7 dB SNHL on the right. Despite conservative treatments, her left hearing did not recovered. MRI scan revealed VS on the right side, which might cause R-SNHL.

Follow-up with MRI scans and PTA evaluations confirmed that the tumor continued to grow up to 16.1 mm x 8.6 mm x 9.2 mm (Figure 1A) and the hearing deterioration in the right ear became worsened (Figure 1B). Finally, she could not communicate even with R-HA (hearing aid; HA) in her daily life in 2012.

### CI Surgery in the Left Ear

As the first stage, CI was performed on the left side with the round window approach (RWA)

### OPEN ACCESS

#### \*Correspondence:

Katsumi Doi, Department of Otolaryngology, Kindai University, 377-2 Oono-Higashi, Osaka-Sayama, Osaka 589-8511, Japan, Tel: +81-72-366-0221 (Ext.3223); Fax: +81-72-366-3641; E-mail: kdoi@med.kindai.ac.jp

Received Date: 17 Oct 2016

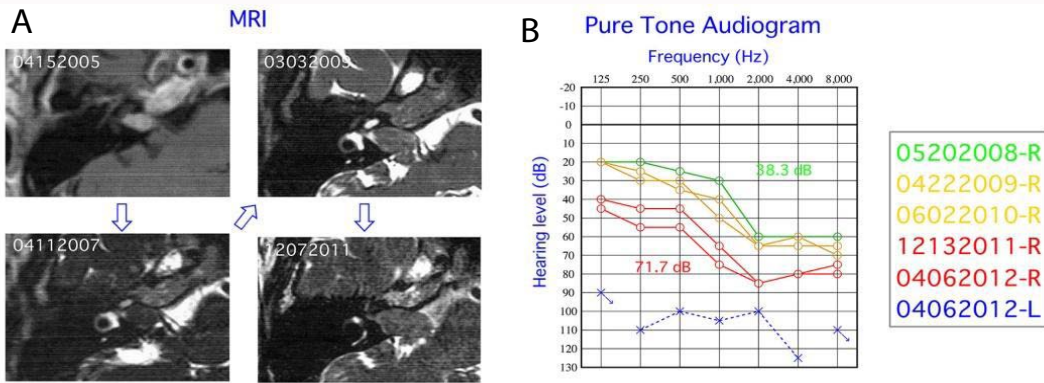
Accepted Date: 06 Dec 2016

Published Date: 08 Dec 2016

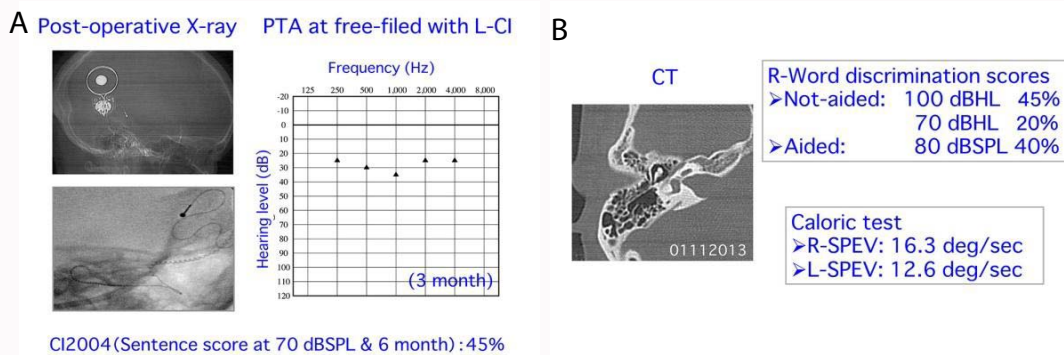
#### Citation:

Doi K, SHiraishi K, Fujita T, Kobayashi T, Sato M, Saito K, et al. Simultaneous Cochlear Implantation with Translabyrinthine Removal of Vestibular Schwannoma. *Clin Surg*. 2016; 1: 1241.

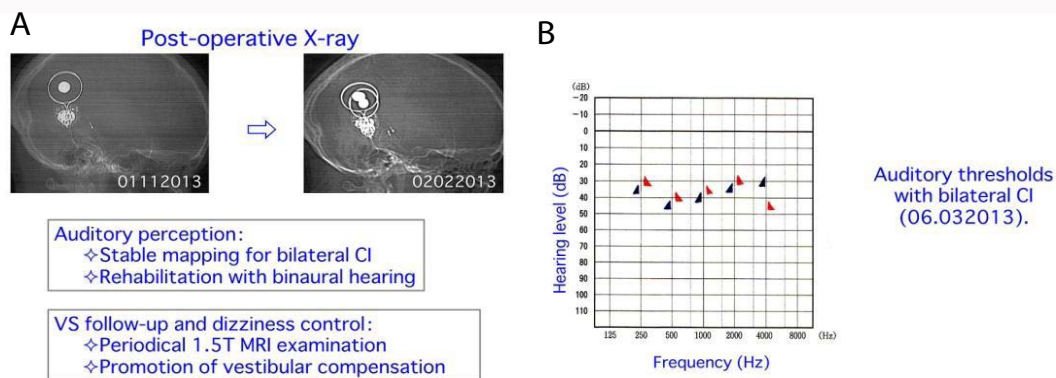
Copyright © 2016 Katsumi Doi. This is an open access article distributed under the Creative Commons Attribution License, which permits unrestricted use, distribution, and reproduction in any medium, provided the original work is properly cited.



**Figure 1A:** MRI scans demonstrated relative rapid tumor growth.  
**Figure 1B:** PTA indicated a profound deafness in the left ear and a progressive hearing deterioration in the right ear.



**Figure 2A:** CI surgery was successfully completed on the left side and free-field PTA was stable after 3 months.  
**Figure 2B:** Speech discrimination test on the tumor side further deteriorated, while the caloric test showed positive responses on both sides.



**Figure 3A:** Second CI was simultaneously performed with TLS tumor removal. Auditory rehabilitations and MRI and CT scans have been conducted.  
**Figure 3B:** Free-field PTA was stable around 30-40 dB on both sides.

in 2012 (Figure 2A). Neural Telemetry test (NRT) showed good responses at all electrode arrays and dexamethasone was administered intra- and post-operatively for preservation of both hearing and vestibular functions. Free-field PTA with L-CI is stable around 30 dB after 3 months (Figure 2A). Speech discrimination test on the left side showed 45% correct in sentences at 6 months after the surgery, while that on the tumor side further deteriorated (Figure 2B). She became to be able to communicate even only with L-CI. The caloric test after the surgery indicated good preservation of the vestibular function in the left ear (Figure 2B).

### CI Surgery in the Right Ear

As the second stage, translabyrinthine removal of VS with

simultaneous CI surgery on the tumor side was performed in 2013 (Figure 3A). The tumor was totally removed, while anatomical preservation of the cochlear nerve was confirmed. Full and smooth insertion of the electrode arrays was done again via RWM. NRT test showed poor but positive responses at a few electrodes. Dexamethasone was again used to preserve the cochlear function as the same manner. No peri- and post-operative complication was noted.

Speech test in the right ear showed 15% correct in sentences at 6 months after the surgery and it had continued to improve up to 36% correct in words and 46% correct in sentences at 1 year after the surgery. Free-field PTA with CI is stable at 30-40 dB on both sides

(Figure 3B). NRT responses were successfully detected more than 10 electrodes on the tumor side with R-CI, and it remained stable on the opposite side thereafter.

## Discussion

The natural history of vestibular schwannoma (VS) leads to profound deafness that is one of the most important predictors of quality of life [1,2]. Therefore, the optimal hearing preservation is one of the priorities in management of VS. The traditional approach has been to wait for hearing loss before surgery to preserve function for as long as possible. While this might allow continuous tumor growth, increase the risk of surgery and should lost a chance of preservation of hearing as well as the cochlear nerve. In such cases, auditory brainstem implantation (ABI) would be adopted, however, hearing outcomes using ABI are known to be usually poor [1-3]. Another option is early intervention to remove the tumor while small. This should reduce the risk of surgery, and offer the opportunity to attempt for preservation of the cochlear nerve as well as good hearing outcomes with cochlear implantation (CI) [1-5].

The present study demonstrates that it is possible to remove the tumor completely, preserve the cochlear nerve, and successfully restore hearing with CI in the operated ear. According to this strategy, translabyrinthine surgery (TLS) should be favorable, because with this approach the entire length of the cochlear nerve is visualized from the fundus of internal auditory canal (IAC) to the brainstem, therefore, the procedure should avoid unvisualized manipulation of the cochlear nerve [1-5]. The previous reports suggest that the tumor size of cerebellopontine angle (CPA) should be 10 mm or less for the cochlear nerve preservation with TLS as the cochlear nerve is difficult to preserve beyond this size [1,2]. TLS with CI should be considered if the tumor is growing and the hearing is unserviceable or becoming worse. The same strategy should be considered to prevent the tumor extension deep into the cochlea if the small intralabyrinthine VS were found. In some cases, just like ABI, CI implanted on the operated side might serve as the sleeper until the hearing loss on the opposite side became unserviceable due to some pathology such as VS, idiopathic sensorineural hearing loss, presbycusis, and Meniere's disease [1,2]. On the contrary, CI implanted on the opposite side might also serve as the sleeper or the reservoir even after the hearing on the tumor side would be gradually worse or lost as the result of surgery. In our case, the CPA component of the tumor was still within 10 mm, while the tumor continued to grow up relative rapidly. The hearing level on the opposite side was already profoundly deaf, and the hearing deterioration on the tumor side was becoming more apparent.

There is a rapid accumulation of the evidence that the outcomes with ABI are much more variable than with CI, and CI after TLS could be much more successful, with hearing outcomes similar to the best postlingual ordinary CI adult cases [1-3]. According to the peer-reviewed literatures, the relative high scores (at least more than 50%) in the open-set speech discrimination were confirmed among the patients who have undertaken TLS with CI [2,3,5]. One factor associated with poor outcomes would be absence of hearing sensation on pre- & post-operative promontory stimulation testing and/or intra-operative electrical auditory brainstem responses (eABR), ABR, and the cochlear nerve compound action potential (CNAP). A good quality eABR and CNAP is a reasonable indicator of good outcomes, while a poor responses is less predicative of poor outcomes [1,2]. In our case, intra-operative neural telemetry testing (NRT) after insertion of the electrode arrays into the cochlea was performed to

monitor the function of the cochlear nerve on both sides during the surgery. We could detect excellent NRT responses on the opposite side and poor but positive responses at least at some electrodes even after total removal of the tumor, indicating the preservation of the cochlear nerve even on the tumor side. We sometimes experience poor NRT responses even during the ordinary CI surgery, presumably due to functional changes of the cochlear nerve, too. However, these functional changes would be temporal and reversible in most cases, because we usually could get vivid NRT responses after initiation of CI system even in those cases, just as in our case.

Another factor associated poor outcomes with CI should be a delay in CI surgery after tumor removal, which may result in cochlear fibrosis and/or ossification [1-5]. It is well recognized that TLS is highly destructive method and cochlear fibrosis and/or ossification might occur in a relative short time. The delay in decision making of CI insertion would allow total fibrosis and/or ossification which means CI placement might be no longer possible. In our case, simultaneous CI surgery with TLS was performed where full insertion of the electrode arrays was completed without any difficulties, resulted in successful hearing outcomes.

Today, we have two options for the hearing preservation in VS surgery, one is CI and another one is ABI [1-5]. Even though CI requires the preservation of the cochlear nerve after the tumor removal, hearing outcomes seem better with CI than with ABI. Whether CI or ABI was implanted, an important issue is the necessity of follow-up with MRI test in all VS cases. The patients are known to have potential risks such as device failure, device and magnet displacements, and local heating during the MRI scans [1,2]. The progress in devices of both CI and AB now makes it possible to have 1.5 T MRI safely, although there should be some precautions such as the use of a compression bandage over the implant [1,2]. Combination of MRI with high-resolution computed tomography (CT) scans would be of benefit and also recommended.

## Conclusion

Decision making in patients with VS in the only hearing ear is challenging. Restoration of hearing when they become deaf will depend on the status of the remaining cochlear and the integrity and function of the cochlear nerve. In terms of hearing restoration, CI is the most effective option if the cochlear nerve could be preserved intact and the cochlea could be remained responsive to electrical stimulation. ABI would be another option for the patients in which the cochlear nerve could not be spared during VS removal, while the hearing results with an ABI are still far poor than those with a CI. If CI is being considered, it should be performed near the time of the surgery for VS removal, because cochlear fibrosis and/or ossification in the cochlea might occur in a short time after the surgery. When the TLS for tumor removal is selected, CI surgery should be done as close as possible to the procedure.

## References

1. Tysome JR, Axon PR, Donnelly NP, Evans DG, Ferner RE, O'Connor AFF, et al. English consensus protocol evaluating candidacy for auditory brainstem and cochlear implantation in neurofibromatosis type 2. *Otol & Neurotol.* 2013; 34: 1743-1747.
2. SKW Lloyd, Glynn FJ, Rutherford SA, King AT, Mawman DJ, O'Driscoll MP, et al. Ipsilateral cochlear implantation after cochlear nerve preservation vestibular schwannoma surgery in patients with neurofibromatosis type 2. *Otol & Neurotol.* 2013; 35: 43-51.

3. Ozdek A, Bayir O, Donmez T, Ozisik P, Safin M, Tulgar M, et al. Hearing restoration in NF2 patients and patients with vestibular schwannoma in the only hearing ear. Report of two cases. *Am J Otolaryngol.* 2014; 35: 538-541.
4. Schutt CA, Kventon JF. Cochlear implantation after resection of an intralabyrinthine schwannoma. *Am J Otolaryngol.* 2014; 35: 257-260.
5. Di-Lella F, Merkus P, Di-Trapani G, Taibah A, Guida M, Sanna M, et al. Vestibular schwannoma in the only hearing ear: role of cochlear implants. *Ann Otol Rhinol Laryngol.* 2013; 122: 91-99.